

# Immune sustainability on titanium implants?

## Osteoimmunology and osseointegration as an interplay of dissolved titanium particles

Drs Johann Lechner, Fabian Schick, Florian Notter, Germany

**Bone-to-implant contact (BIC)** is considered an essential requisite for implant stability and clinical success. The death of local bone marrow cells due to chronic stimulation as a result of unfavourable factors such as inflammation of the jawbone leads possibly to chronic osteoimmune dysregulation. Bone marrow defects of the jaw (BMDJ) surrounding dental titanium implants (Ti-Impl), in combination with impaired BIC, are difficult to detect in X-rays and have thus been little researched. Recent research shows that Ti-Impl can induce inflammation in the surrounding bone over time.<sup>1,2</sup> Can alveolar bone decay possibly induce local osteoimmune reactions? In earlier publications we defined this chronic inflammatory process as fatty-degenerative osteonecrosis (FDOJ/BMDJ) connected to chronic overexpression of proinflammatory cytokine RANTES/CCL5.<sup>3,4</sup> FDOJ/BMDJ is a lesion also primarily defined as “bone marrow edema”<sup>5,6</sup> or as silent or subclinical inflammation without the typical signs of acute inflammation (Fig. 1). Is an undetected transition

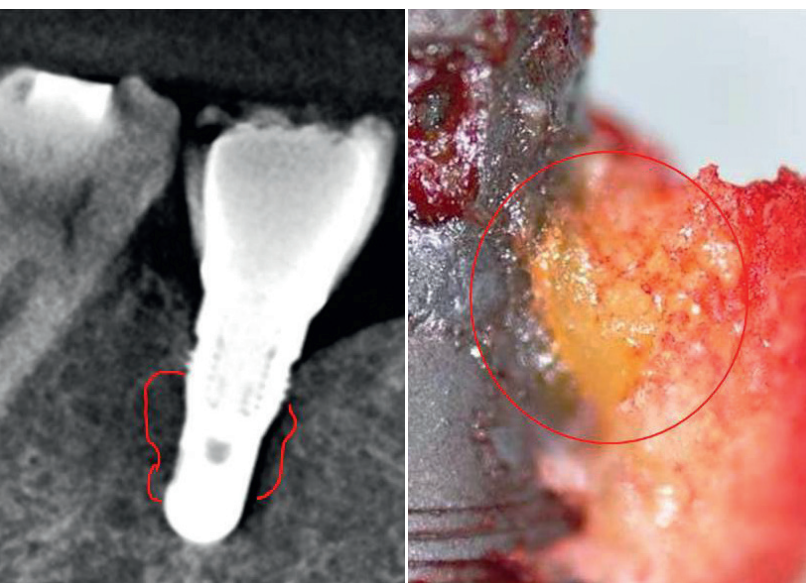
existing from diminished bone-to-implant contact (BIC) to hitherto neglected osteonecrosis? This opens up a new case in implantology:

### The long-term immune sustainability of dental implants

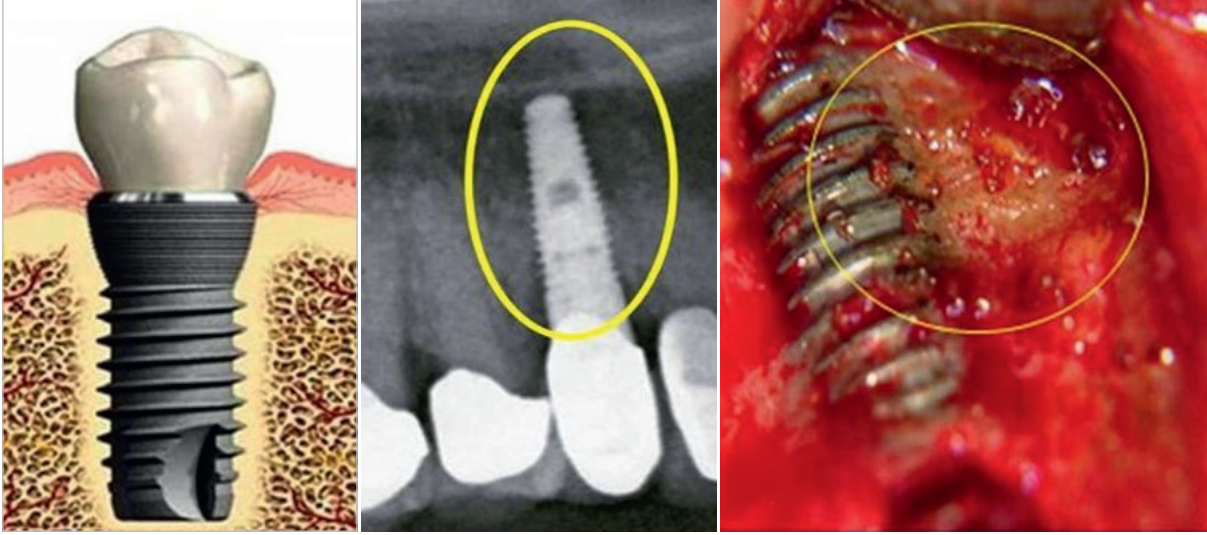
Osseointegration, defined as “functional ankylosis” between implant and jawbone, is the primary treatment objective in implantology. Osseointegration is the direct structural and functional connection between living bone and the surface of a load-bearing artificial implant.<sup>10</sup> Successful osseointegration occurs where new bone is deposited directly at the bone–implant interface and the implant exhibits mechanical stability.<sup>11</sup> Figure 2 explains a diminished osseointegration in three steps: ideal theory, the radiographic display and the actual reduced BIC, converted to FDOJ/BMDJ.

### The connection of incomplete BIC to osteoimmune inflammation

However, what if this BIC does not take place over the entire surface of the implant? In those areas where osseointegration is impaired, chronic inflammation may occur to the immunological detriment of the patient.<sup>12</sup> Bone cells interact with immune cells under physiological and pathological conditions.<sup>13</sup> Researchers find that osteoimmunology is a core area of knowledge for interpreting implant outcome. The immune and healing responses are not only transient one-time reactions, but instead represent a temporal continuum of dynamic hard- and soft-tissue changes.<sup>11</sup> Following multiple reports in the literature concerning dissolved TI particles in the surrounding bone,<sup>7,8</sup> we analysed the osteoimmune dysregulation of 14 post-operative jawbone samples from patients with BMDJ around Ti-Impl.<sup>9</sup> The multiplex analysis of seven cytokines in 14 FDOJ/BMDJ samples showed a singular overexpression of chemokine RANTES/CCL5 (red columns), compared to the healthy jawbone group (n = 19; blue columns) in Figure 3.



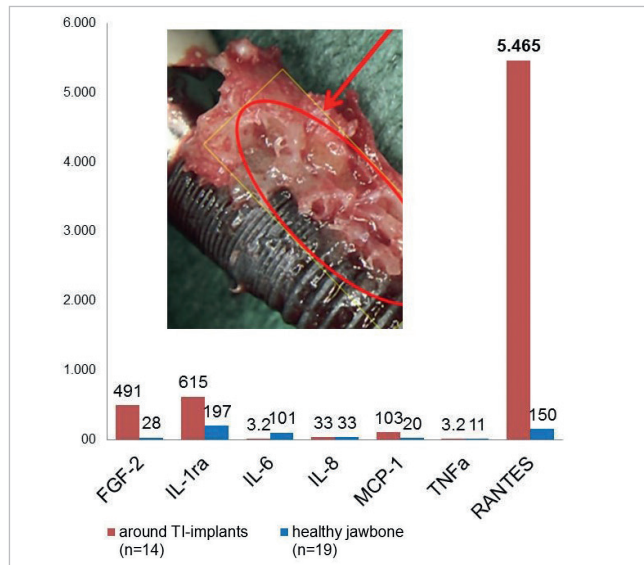
**Fig. 1:** Titanium implant as shown in CBCT; fatty-degenerated FDOJ/BMDJ attached directly to the Ti-Impl.



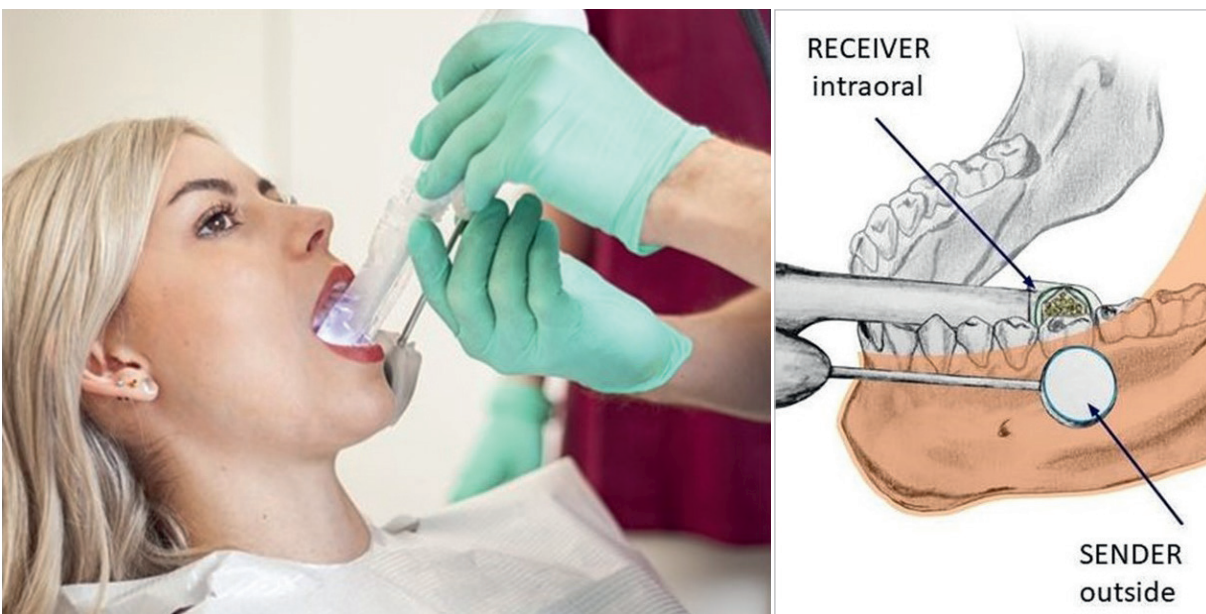
**Fig. 2:** Left: Ideal theory. Centre: Radiography. Right: The actual reduced BIC, converted to FDOJ/BMDJ. Attachment of fatty-degenerative bone (BMDJ) to Ti-Impl (area 13); X-ray does not indicate inflammatory bone loss or significant peri-implantitis.

### How to diagnose the osteoimmune sustainability of the BIC?

Why is this FDOJ/BMDJ osteoimmune decay and connected RANTES/CCL5 overexpression at implant to bone interfaces not detectable in OPG/CBCT? The answer is well known as “X-ray artefacts”.<sup>15</sup> The biological implant–bone boundary (BIC) cannot be correctly structurally reconstructed for these technical reasons.<sup>16</sup> Previous research demonstrated the non-visibility and lack of obvious radiographic signs of FDOJ/BMDJ.<sup>17</sup> As a result, the existence of FDOJ/BMDJ and its osteoimmune implications are largely neglected in implantology. However, no technique has yet been developed to visualise and verify whether bone or soft tissue is actually present around implants.<sup>18</sup> While conventional X-ray techniques are limited in their ability to reveal the actual extent and location of FDOJ/BMDJ, other means of identifying osteoimmune decay at implants are available.<sup>19</sup>




**Fig. 3:** Expression analysis of seven cytokines in 14 FDOJ/BMDJ samples (red columns), compared to the healthy jawbone group (n = 19; blue columns). Picture displays example of adjacent FDOJ/BMDJ sample at implant.



**Fig. 4:** Radiation-free measurement of jawbone density using a TAU device.





**Fig. 5:** Implant area 16 with no detectable FDOJ/BMDJ or osteoimmune dysfunction on BIC in OPG (left) and CBCT (right). Below OPG the sonographic displaying bone density in red (soft and inflammatory) and in green (healthy jawbone).

To aid the practitioner in diagnosing the osteoimmune FDOJ/BMDJ softening, a computer-assisted transalveolar ultrasound (TAU) device is available.<sup>20,21</sup> Due to these diagnostic difficulties FDOJ/BMDJ is underdiagnosed by dentists. For the research in Figure 3<sup>9</sup> all patients had a panoramic OPG, a CBCT and additional measurement of jawbone density using the new TAU device. TAU is to establish the presence of diminished BIC and connected FDOJ/BMDJ.<sup>14</sup> TAU measurements are based on ultrasonic principles where sound is best conducted through solid material and more weakly in aqueous environments. The device consists of an ultrasonic transmitter that is placed on the skin over the specific jaw area to be

measured. A receiver of the size of a thumbnail is placed opposite intra-orally. Interference-free acoustic coupling is achieved with gel pads placed both intra-orally and extra-orally (Fig. 4).

### TAU bone density measurements

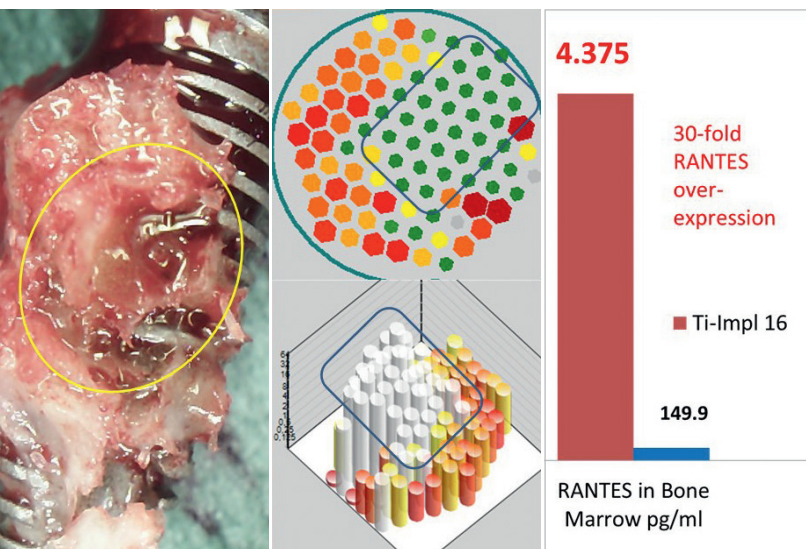
The ultrasound waves are converted into a coloured pulse via a computer unit whereby sound waves of varying attenuations are represented in red for diminished bone density and in green for solid cancellous bone (Figs. 5 & 6). Figure 5 and the clinical example of a Ti-Impl area 16 show the problem: Is there any detectable FDOJ/BMDJ or osteoimmune dysfunction on BIC? Figure 6 displays the postoperative FDOJ/BMDJ at implant (left), the TAU picture with implant in green and surrounding osteonecrosis in red (centre) and the multiplex analysis of overexpressed RANTES/CCL5 signaling (right).

### The misleading problem for the clinician


The problem for the clinician in this context is:

- a. the clinical stability of the Ti-Impl leads to the misdiagnosis of an apparently inflammation-free osseointegration;
- b. the radiographic and clinical inconspicuousness and
- c. the long term symptoms of an osteoimmune inflammation connected to diminished osseointegration are not directly related to the Ti-Impl as they occur only after a certain amount of time.<sup>22</sup>

As a result, an osteoimmunological scenario is conceivable, as shown in Figures 5 and 6. Accordingly, a purely clinical and symptom-focused assessment of Ti-Impl is insufficient and needs clinical support by TAU (see [www.cavitaui.de](http://www.cavitaui.de)). X-rays also fail to indicate the derailed mediator process (cytokines, interleukins) triggered by FDOJ/BMDJ at implants. In failing to recognise this, detrimental local and systemic health consequences may occur in the host that are concealed by the apparent success of a “stable implant”. The challenge posed by these discoveries is the need to raise awareness of the potentially critical interplay between Ti-Impl and FDOJ/BMDJ.



**Fig. 6:** Postoperative picture of Ti-Impl 16 with attached FDOJ/BMDJ osteoimmune decay and with multiplex analysis of inflammatory RANTES/CCL5 overexpression.



### contact

**Dr Dr (PhD) Johann Lechner**  
 Head of Clinic for Integrative Dentistry  
 Grünwalder Straße 10 A  
 81547 München, Germany  
[drlechner@aol.com](mailto:drlechner@aol.com)  
 +49 89 6970129

